Anal canal and Peri anal disease

M.H.SOMI .MD

PROFESSOR OF GASTROENTROLOGY &HEPATHOLOGY



دکتر فریبا قادری



دکتر حسین بناگذار



دکتر محمد حسین صومی



دکتر امین صدر آذر



دکتر مسعود شیر محمدی

- Anorectal complaints are common:
  - hemorrhoid-related complaints account for more than two million outpatient evaluations annually
- The incidence of anal fissure is estimated to be 1.1 cases per 1000 person-years

- Many anorectal diagnoses share similar symptoms, and benign anorectal conditions share common symptoms with cancers of the anus and rectum.

- As such, a thorough evaluation is critical toward making the correct diagnosis

Anatomy and Terminology

- While a detailed understanding of anorectal anatomy is not required to perform an adequate anorectal examination, it is helpful to understand certain anatomical terminology.

- The anal canal represents the distal 2.5 to 4 cm of the alimentary tract

Anatomy of the anus and rectum

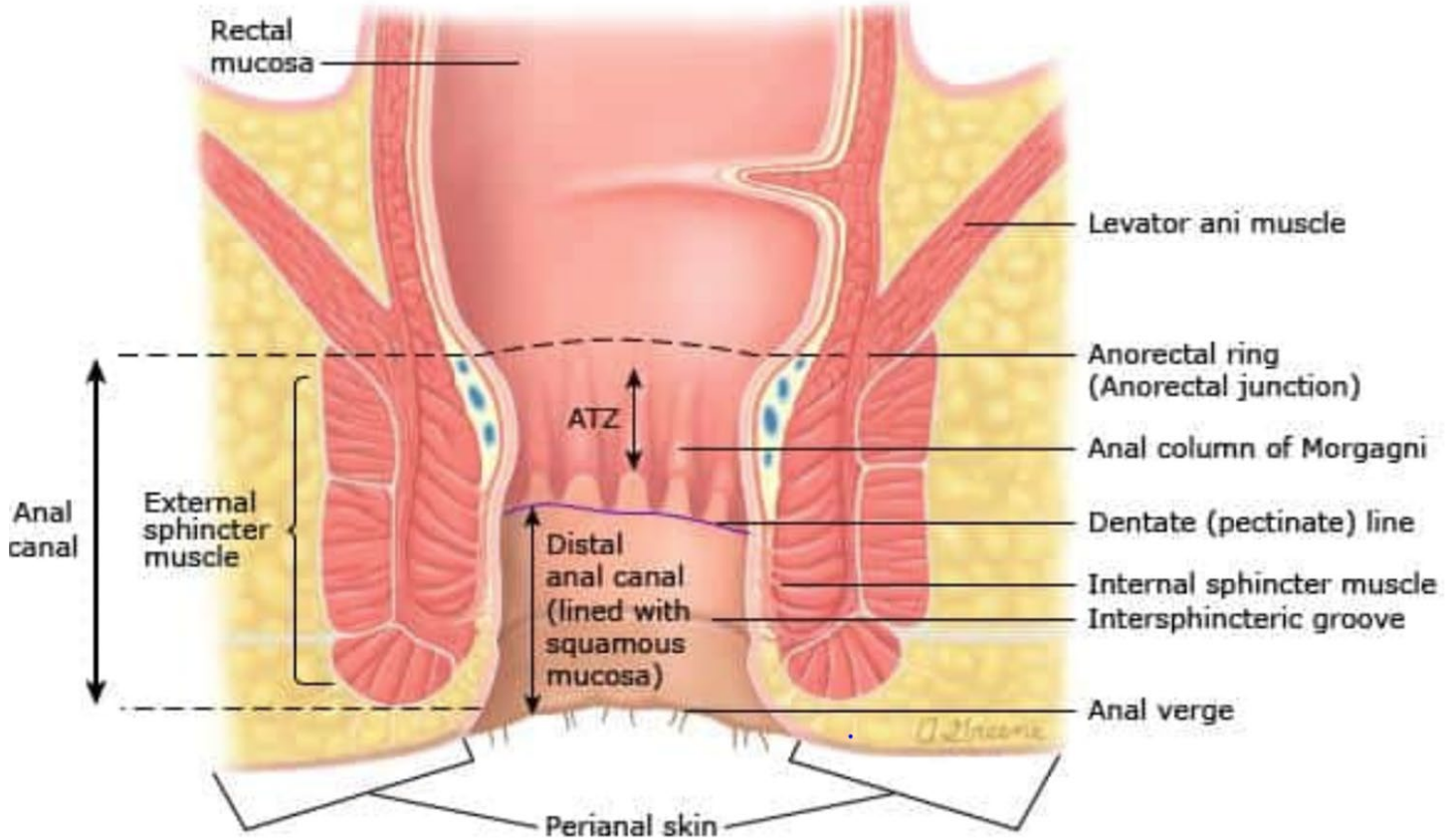

- The anal canal is 2.5 to 4.0 cm long and begins superiorly where the rectal ampulla is narrowed by the anorectal ring.
- This palpable muscular ring is formed by fusion of the puborectalis muscle (part of the levator ani muscle complex) with the more inferior internal and external anal canal sphincters.

- The external anal canal sphincter ends just distally to the internal anal canal sphincter; the intersphincteric groove is the palpable plane that can be palpated between the termination of the two sphincters.
- The presence of the intersphincteric groove coincides roughly with the anal verge, which marks the distal portion of the anal canal.
- The perianal skin extends 5 cm laterally from the anal verge and is characterized by the presence of hair follicles and glands.

- The interior of the anal canal can be divided into proximal and distal portions by an irregular line formed by the anal valves called the dentate (or pectinate) line (colored purple in the diagram).
- The portions of the anal canal proximal and distal to the dentate line have different origins of arterial supply, nerve innervation, and venous lymphatic drainage.
- The squamo-columnar junction (SCJ) lies within the proximal portion of the anal canal and marks the transition between rectal columnar epithelium to anal squamous epithelium.

- The exact position of the SCJ changes with time due to replacement of columnar epithelium with squamous epithelium in a process known as squamous metaplasia.
- The anal transformation zone (ATZ) is the zone where all aspects of squamous metaplasia are currently found and/or have occurred.
- The ATZ is marked by the SCJ proximally and extends distally to approximately the level of the dentate line.

- Lesions that are not completely visible while separating the gluteal cheeks are appropriately referred to as anal lesions.
- If a lesion can be completely visualized with separation of the gluteal cheeks, and if it is within 5 cm of the anal orifice, this lesion would be classified as a perianal lesion.
- Any lesion more than 5 cm from the anus would be considered a skin lesion unrelated to anorectal pathology.
- The rectum is the continuation of the sigmoid colon leading to the anal canal (figure 2). The boundary between the rectum and the anal canal is usually determined endoscopically

Division of the upper, middle, and lower rectum

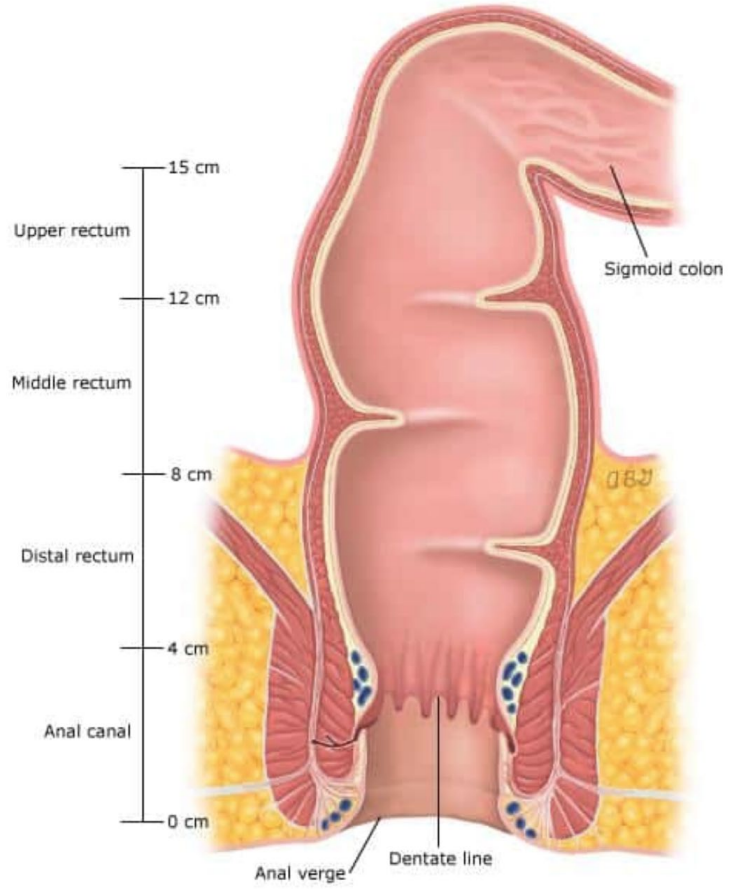

PATIENT HISTORY

- The clinician should first elicit a history of anorectal bleeding, anorectal or perianal pain, perianal drainage, anal pruritus, or the prolapse of tissue through the anal orifice.
- Additionally, the patient's bowel habits should be discussed, including
  - The average number of bowel movements per day
  - The need for moderate or severe straining to defecate
  - The average number of minutes required per defecatory episode
  - The cleaning routine, and
  - Any bowel regimen the patient may use.

PATIENT HISTORY

- The patient should also be inquired about
  - Unintentional weight loss
  - Changes in bowel habits
  - Recurring abdominal distention or abdominal pain.

- Patients with recurring abdominal pain and/or diarrhea should be asked about a family history of IBD.

- Regardless of age, patients should be questioned about prior endoscopic examinations of the large intestine

Patient positioning

- The in-office anorectal examination is best performed in the "prone-jackknife" position, which not only provides optimal visualization but also aligns the laterality of the examiner with the patient.
- However, many medical offices do not have a dedicated examination table to allow patients to assume this position.

- In that scenario, the lateral decubitus position is an acceptable alternative for an awake anorectal examination in most patients.

Complete anorectal examination

- A complete anorectal examination consists of
  - Inspection
  - Digital rectal examination
  - Anoscopy/proctoscopy
  - Endoscopy
- The first three parts are usually achievable in any office setting; endoscopy (ie, sigmoidoscopy or colonoscopy) requires additional equipment or personnel.

Inspection

- The clinician should first gently separate the buttock cheeks to visualize the perianal skin (the 5 cm perimeter surrounding the anal orifice).
- The examiner should denote any gross lesions concerning for anal cancer, perianal abscesses and/or anal fistulas, or external hemorrhoids.
- Any other discrete skin lesions (eg, skin excoriation, condyloma) should also be recorded, including their anatomic location and distance to the anal orifice

Digital rectal examination

- A digital rectal examination should be performed with adequate lubrication, and the clinician should communicate to the patient throughout the examination to optimize patient comfort and compliance.

- A digital rectal examination can evaluate for any mass in the anal canal or lower rectum or a stricture secondary to prior surgeries or Crohn disease.
- Neither anoscopy nor proctoscopy can replace a digital anorectal examination as the distal anal canal is difficult to visualize with an end-viewing endoscope and the introduction of an instrument may obscure a distal lesion that the instrument is trying to detect.
- Such distal lesions are best detected by the digital rectal examination.

- If an anal fissure is suspected by inspection or by point tenderness upon insertion of the tip of a gloved finger, digital rectal examination should be deferred until healing as it would unnecessarily provoke the patient's anal pain.

- In addition to evaluating for palpable abnormalities, digital anorectal examination also allows for a general assessment of pelvic floor and anal sphincter function, which can be helpful in patients with complaints of constipation and/or incomplete anorectal evacuation

- Both the resting and voluntary anal sphincter tone can be assessed by a digital rectal examination, the latter by instructing the patient to "tighten" the external anal sphincter as they would while resisting the urge to defecate or flatulate.

- The puborectalis muscle can be identified by palpation at the anorectal junction, and in patients with functional pelvic floor abnormalities, palpation of this muscle often reproduces a milder form of the patient's presenting complaints of pelvic pain or pressure.
- With the examining digit in this location, a Valsalva maneuver by the patient, as occurs during defecation, should produce relaxation of the puborectalis muscle, with the muscle moving toward the sacrum.
- The absence of relaxation, or paradoxical contraction, can be noted in functional pelvic floor conditions.
- Additionally, the same Valsalva maneuver should be associated with relaxation of the internal anal sphincter; paradoxical contraction of this muscle can be an indication of anal sphincter dyssynergy

Anoscopy or proctoscopy

- An anoscopy is helpful for evaluating for anal condylomata, anal neoplasms, internal hemorrhoids, and anal fissures.

- A rigid proctoscopy is appropriate for identifying the location of rectal neoplasms as well as evaluating for proctitis

Endoscopy

- An anorectal examination is not complete without endoscopy.
- Clinicians should never make assumptions that anal bleeding is secondary to benign anorectal diseases (eg, hemorrhoids), which could lead to a missed diagnosis of colorectal cancer.

- It is recommended that for any patient with anal bleeding, a discussion regarding endoscopy be undertaken and documented.

- For complaints of anorectal bleeding or abdominal pain, a colonoscopy is preferred to sigmoidoscopy because diseases such as colorectal polyps and cancers from any portion of the large bowel can cause these symptoms.

- If a patient has undergone a recent colonoscopy, and/or if the patient's complaints are isolated to the pelvis (eg, pelvic pain), then a more limited endoscopic examination, such as a sigmoidoscopy, may be adequate.

Examination under anesthesia

- Patients are frequently anxious about awake anorectal examination, and past experiences with physically painful anorectal examinations are a frequent contributor to this apprehension
- Thus, if the provider cannot achieve a thorough examination, or if certain invasive tests (eg, biopsy) are required, it may be more prudent to perform the examination under anesthesia in an operating room

SYMPTOM-BASED DIFFERENTIAL DIAGNOSIS

- Pain
  - The clinician should first clarify whether the pain is perianal or anal in location, and if perianal, the exact location(s) of the pain

Perianal pain

- Generalized perianal pain
  - Generalized perianal pain can be caused by pruritus ani, especially when the perianal skin appears grossly normal or with minimal changes, since pruritus ani relates to hypersensitivity of cutaneous nociceptive nerves as opposed to skin changes
- Generalized perianal discomfort is less likely to represent a neoplastic process than is localized perianal discomfort.

- Localized perianal pain
  - Localized perianal discomfort can be related to skin trauma, external hemorrhoids, perianal abscess, or perianal neoplasms.
    - Perianal condylomata do not cause discomfort.

Perianal pain

- Thrombosed external hemorrhoids are a very common cause of localized perianal pain.
- Their appearance establishes the diagnosis, with enlarged and tender perianal lesions
- that could cause ulceration of the overlying skin (picture 2) and/or extrude clot (picture 3).
- If the patient is evaluated within 72 hours of the thrombosis, the clinician can consider a bedside incision and thrombectomy, though this intervention is associated with the risk of recurrences.
- If the patient presents after 72 hours, operative intervention is usually avoided since the patient's discomfort will soon begin to noticeably improve.
- Regardless of time of presentation, if nonviable skin is noted with a thrombosed external hemorrhoid, urgent surgical consultation is required.

Thrombosed external hemorrhoid



Circumferential thrombosed hemorrhoids – Hemorrhoidal crisis



Thrombosed external hemorrhoids

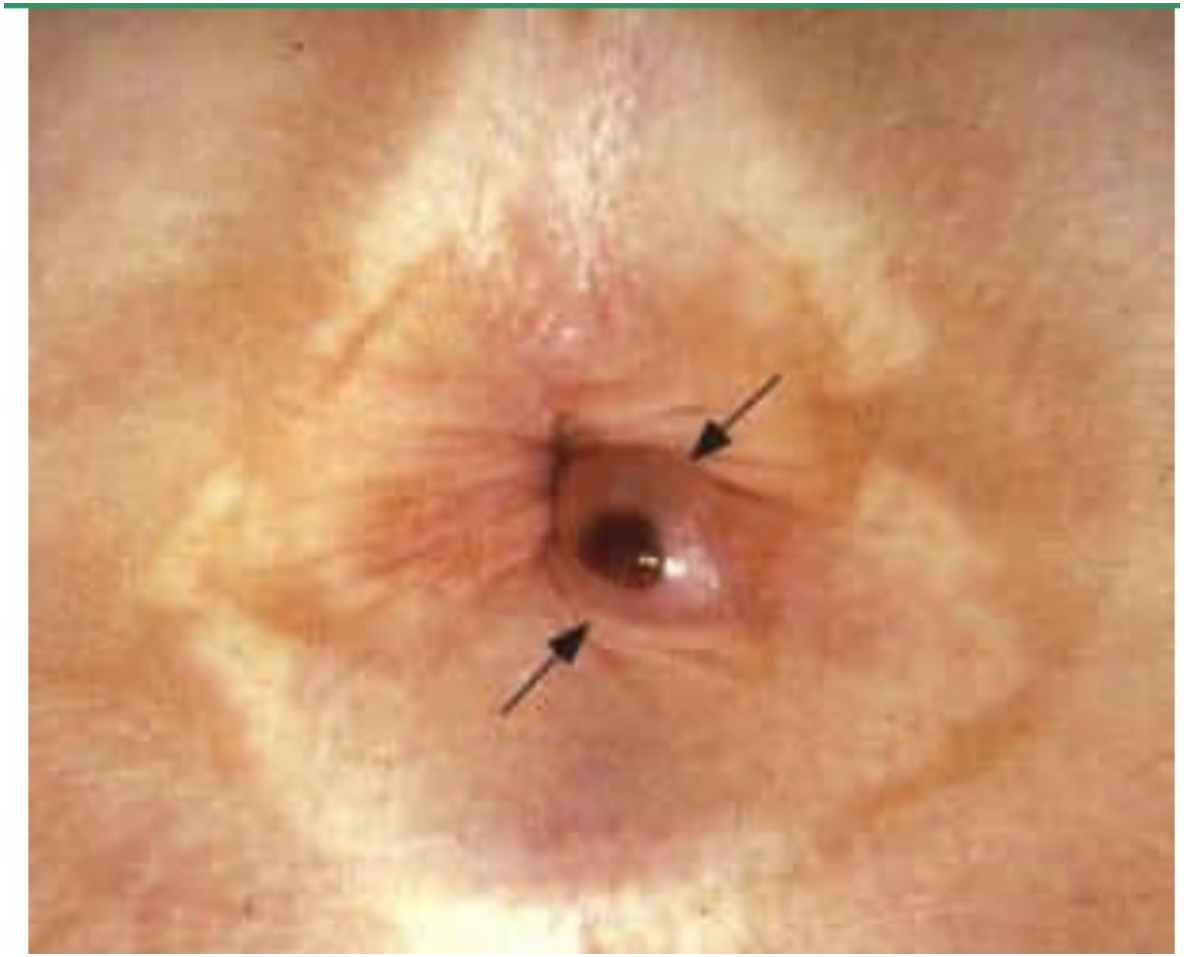

- Perianal abscesses can create perianal discomfort, often associated with other symptoms such as fevers or perianal drainage.
- Physical examination frequently reveals erythema of the overlying skin, with or without induration and/or fluctuance

- For most perianal abscesses, an incision and drainage procedure is required urgently

Perianal abscess



Anal canal pain

- Discomfort arising within the anal canal may be related to anal fissure, anal cancer, or anal ulceration caused by STD.
- Internal hemorrhoids generally do not cause anal pain.
- Anal fissure should be suspected in patients who complain of severe anal pain but have no visible perianal source of discomfort.
- Pain from an anal fissure may be constant but further exacerbated by defecation.
- In such patients, gentle digital palpation of the anal verge (the skin surrounding the anal orifice) at the posterior or anterior midline may identify point tenderness, which is sufficient to establish a provisional diagnosis (picture 5).
- In one to two subsequent visits (four to eight weeks), an interval digital rectal examination/anoscopy may be performed once the patient's anal pain has improved or resolved with medical therapy.
- Anal cancers can produce symptoms similar to those of an anal fissure, mandating that a digital anal examination be performed as part of the evaluation, though not necessarily at the initial encounter when the pain may make a digital examination unbearable

Anal fissure

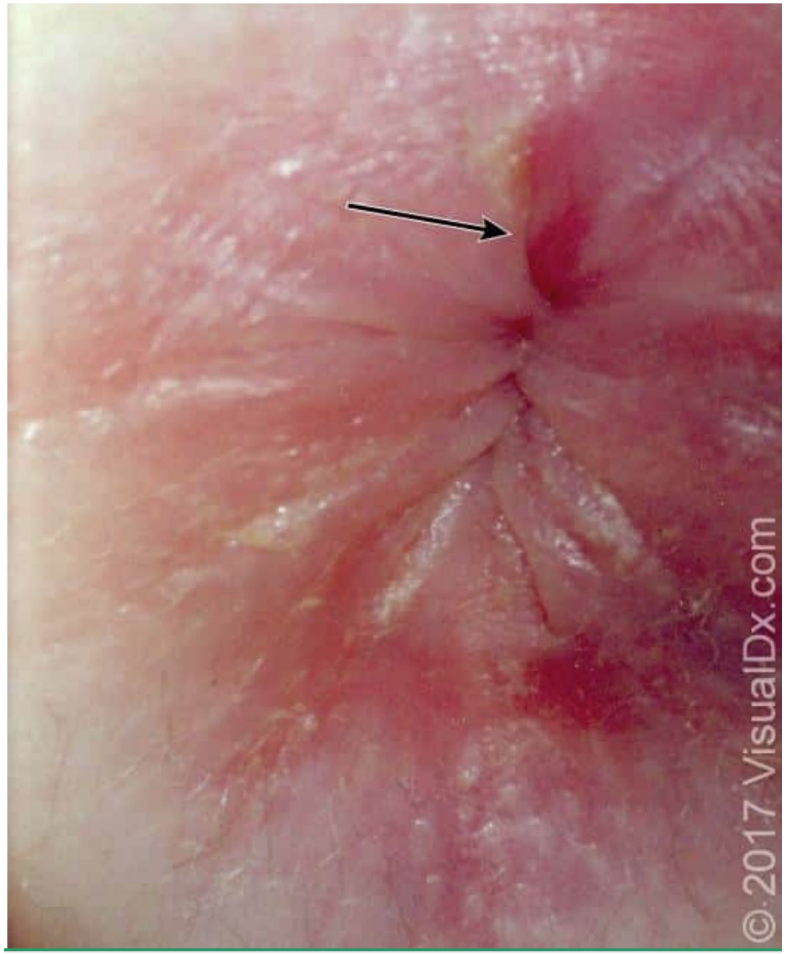

Bleeding

- Bleeding is a common complaint in patients with anorectal problems.
- Bleeding from the anal canal can be secondary to diseases, including anal fissures, internal hemorrhoids (external hemorrhoids are generally not a source of bleeding except when thrombosed and extruding clot), or anal neoplasms.
- A digital anorectal examination can detect palpable neoplasms in the anal canal.
- An anoscopy is helpful in evaluating for enlarged or bleeding internal hemorrhoids and, if indicated, facilitating rubber band ligation or other treatments of internal hemorrhoids.
- If bleeding is accompanied by severe anal pain provoked by defecation, an anal fissure may be present.

Grades of internal hemorrhoids

Grade	Symptoms	Exam	Treatment	Illustration
1	Painless bleeding	Hemorrhoid with vascular engorgement bulging into anal canal without prolapse	First-line: Medical Second-line: Office procedures (eg, RBL)	
2	Painless bleeding, perianal itching	Hemorrhoid prolapses with straining but reduces spontaneously	First-line: Medical Second-line: Office procedures (eg, RBL)	
3	Painless bleeding, perianal itching, swelling, staining or soilage with mucus/ feces	Hemorrhoid prolapses beyond the dentate line with straining and is only reducible by manual pressure	First-line: Medical Second-line: Office procedures (eg, RBL)	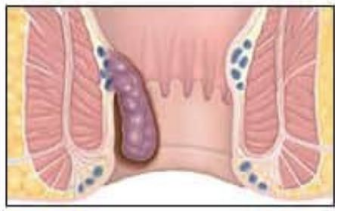
4	Pain, bleeding, swelling, soilage with mucus/feces	Grossly evident prolapse of hemorrhoid tissue that is non-reducible; chronic inflammatory changes (mucosal atrophy, friability, maceration, and ulceration)	Surgical excision	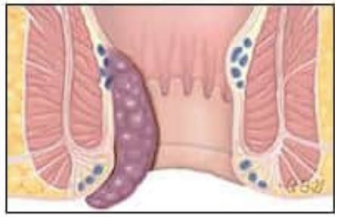

Treatment Options for Internal Hemorrhoids

Type of Treatment	Hemorrhoid Grades	Success Rate	Comments
General			
Diet (increase in fiber and fluids) and bowel habit modification	1-4	Unknown	Patients with all grades of hemorrhoids should use these measures (see text)
			Patients with high grades of hemorrhoids will need additional therapy
Endoscopic			
Sclerosing agent	1-4	75%	May be the favored treatment of patients with AIDS (successful results even with grade 3 and 4 hemorrhoids)
			Life-threatening sepsis rarely complicates therapy
Rubber band ligation	2 and 3	65%-75%	Grade 1 hemorrhoids are too small, and grade 4 hemorrhoids are usually too large for this procedure
			The most commonly performed office procedure for hemorrhoids
			Life-threatening sepsis rarely complicates therapy; 1% risk of severe hemorrhage when band sloughs
Infrared coagulation	1 and 2	Less than for rubber band ligation	Equipment for the procedure is expensive
			Rare complications
Surgical			
Excisional hemorrhoidectomy	3 and 4	>85% on 10-year follow-up	External tags may be removed at the time of the surgical procedure
			Postoperative pain is pronounced
Procedure for prolapsing hemorrhoids (PPH) *	3 and 4	>75%; several studies show higher long-term recurrence rates than with excisional hemorrhoidectomy	Newer procedure
			Overall, significantly less postoperative pain than with excisional hemorrhoidectomy, but some patients experience severe, persistent postoperative pain or defecation urgency
			Pelvic sepsis and death have been reported after this procedure

Rubber band ligation of internal hemorrhoid



- Again, it is important to remember that without a colonoscopy, a malignancy in the large intestine cannot be definitively excluded.
- Therefore, all patients who present with anorectal bleeding should undergo a diagnostic colonoscopy, unless there is a compelling reason to omit this examination (such as a colonoscopy within three to five years, and preferably with this prior colonoscopy having been performed when the patient was already experiencing bleeding).
- Young adult age is not a reliable reason for omitting a colonoscopy in these circumstances.
- In some studies, the incidence of colorectal cancer is rising in patients younger than 50 years of age

Prolapsing tissue

- Patients may complain of a "lump" at the anus that is either present continuously or "comes and goes.“
- Patients who complain of tissue prolapsing from the anal canal most often have either prolapsing internal hemorrhoids or rectal prolapse.
- One of the most reliable methods of distinguishing the two involves the patient sitting on a commode in clinic, straining as they would during the act of defecation in an attempt to reproduce the symptom for the clinician to visualize.

- Rectal prolapse has a distinct appearance, with prolapsed rectum often demonstrating concentric folds involving tissue that occupies the circumference of the anal canal

Rectal prolapse – complete



- Prolapsing internal hemorrhoids often appear in "clusters" that are predominantly within quadrants surrounding the anal orifice (picture 8).
- The tissue has a grossly distinct appearance from rectal mucosa, and if the prolapse is chronic, the tissue may demonstrate a thicker, squamous, and almost verrucous appearance due to squamous metaplasia.
- Prolapsing internal hemorrhoids may reduce spontaneously or require manual reduction. In the most severe cases, prolapsing internal hemorrhoids may be irreducible.

- Patients with enlarged internal hemorrhoids are very likely to also have some degree of external hemorrhoidal enlargement, and since external and internal hemorrhoids are separated by only a few centimeters, it may be difficult to distinguish prolapsing internal hemorrhoids from enlarged external hemorrhoids.
- Young and/or nulliparous female patients may develop either prolapsing internal hemorrhoids or rectal prolapse due to chronic constipation.
- Straining at defecation can cause stretch pudendal neuropathy, which can lead to the anal canal to open more than normal.
- his can then allow anal canal tissue, including internal hemorrhoids, to momentarily prolapse or give the sensation of prolapse. In such patients, the treatment should be focused on the underlying constipation

Prolapsed internal hemorrhoids

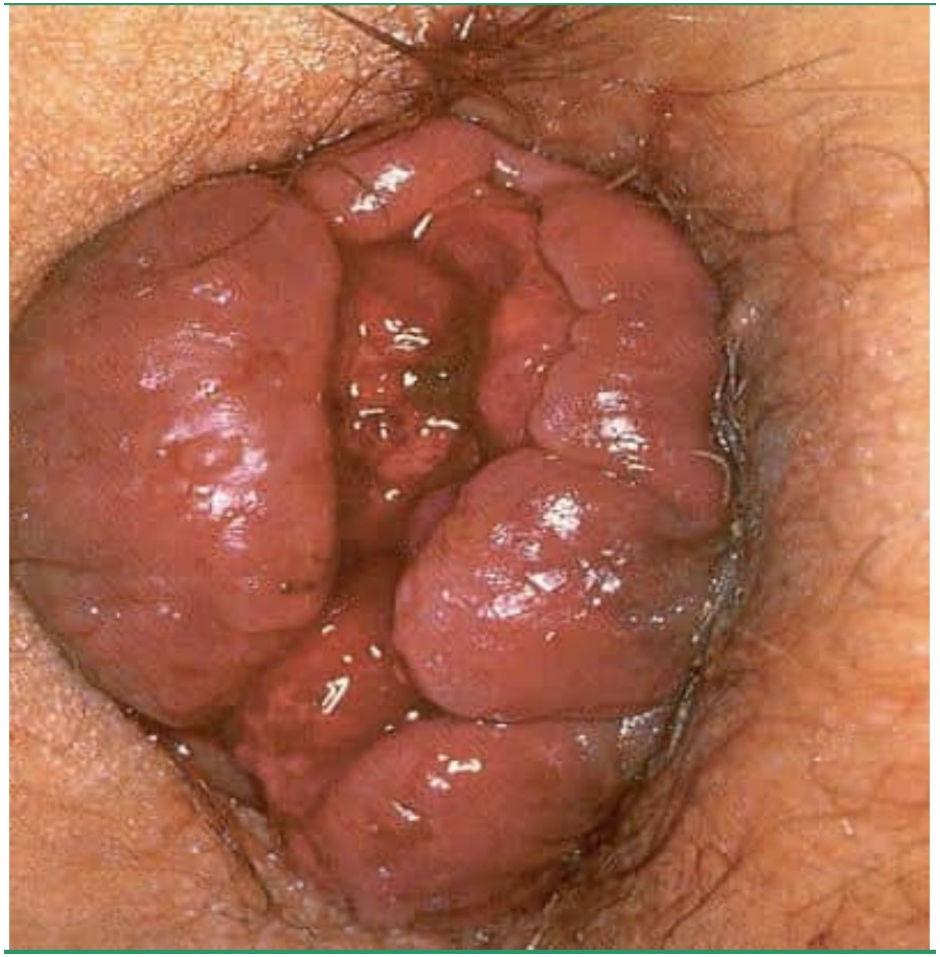

Pruritus

- Anal pruritus is perhaps the most difficult complaint to manage as it is frequently associated with idiopathic causes.
- The patient should be queried about the laterality and exact location of the symptoms, although pruritus is often a generalized, circumferential complaint.
- Although patients often complain of intense itch, burning, or irritation, the perianal skin frequently appears grossly normal.
- This discrepancy between symptoms and physical findings reflects cutaneous hypersensitivity of nociceptive fibers in the setting of idiopathic pruritus ani

Perianal drainage

- Perianal drainage can be caused by
  - Anal fistula
  - Fecal incontinence
  - Other skin conditions such as pilonidal cyst, perianal hidradenitis, and perianal skin cysts (eg, sebaceous cyst).

- Anal fistula can produce either purulent or serosanguinous drainage.
- The presence of an anal fistula is associated with a nodular, discrete opening within the perianal skin
- Any associated symptoms, such as erythema, induration, or fluctuance, should be noted as fistulas that are not draining adequately can lead to abscess formation.
- Fecal incontinence, if predominantly involving a mucoid discharge, can be described by patients in terms similar to those fitting an anal fistula.

- Examination in this setting would reveal no evidence of an anal fistula, but diminished resting sphincter tone.

Simple anal fistula



- Pilonidal diseases usually present with symptoms of pain and/or drainage
- However, drainage from a pilonidal cyst can usually be traced to the gluteal cleft rather than the perianal area.

- Perianal hidradenitis can produce perianal drainage that is either purulent or sanguineous.

- This disease is also characterized by discomfort, both from chronic inflammation as well as from local abscess formation that may require incision and drainage.
- Hidradenitis can be diagnosed by the presence of subcutaneous sinus tract formation, often with an arborizing system of tracts
- Other perianal skin lesions such as sebaceous cysts can be associated with drainage if secondarily infected.
- Just as in other areas of the body, sebaceous cysts in the perianal area are associated with a well-circumscribed, often raised area that may demonstrate a central punctum)

Pilonidal disease masquerading as possible anal fistula

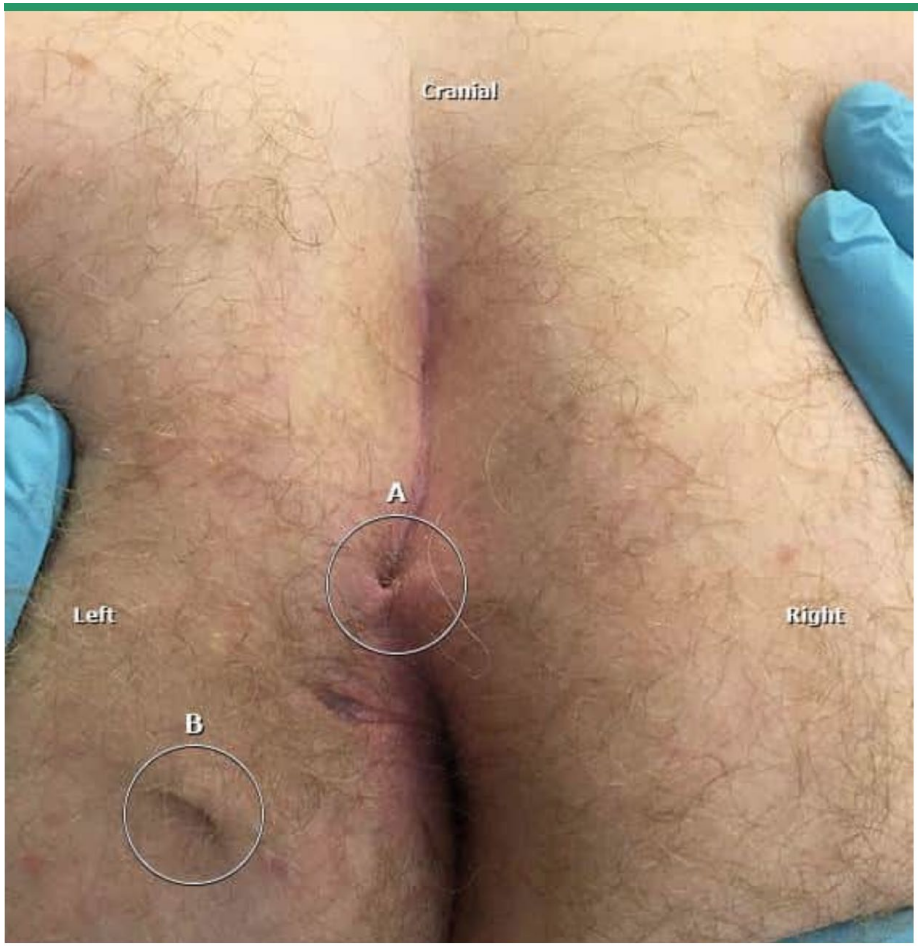

Hidradenitis suppurativa

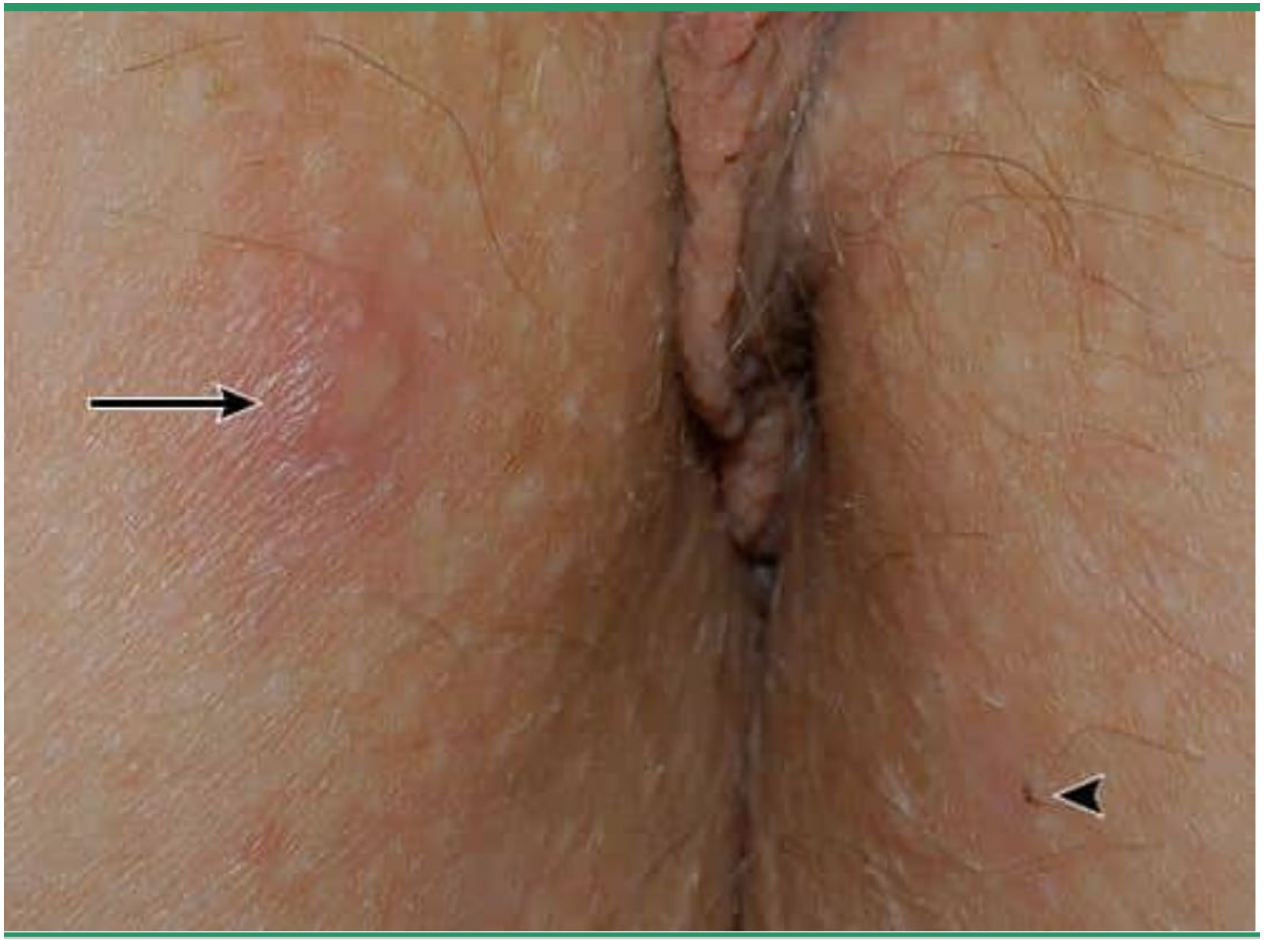

Epidermoid cyst



با تشکر از توجه شما

